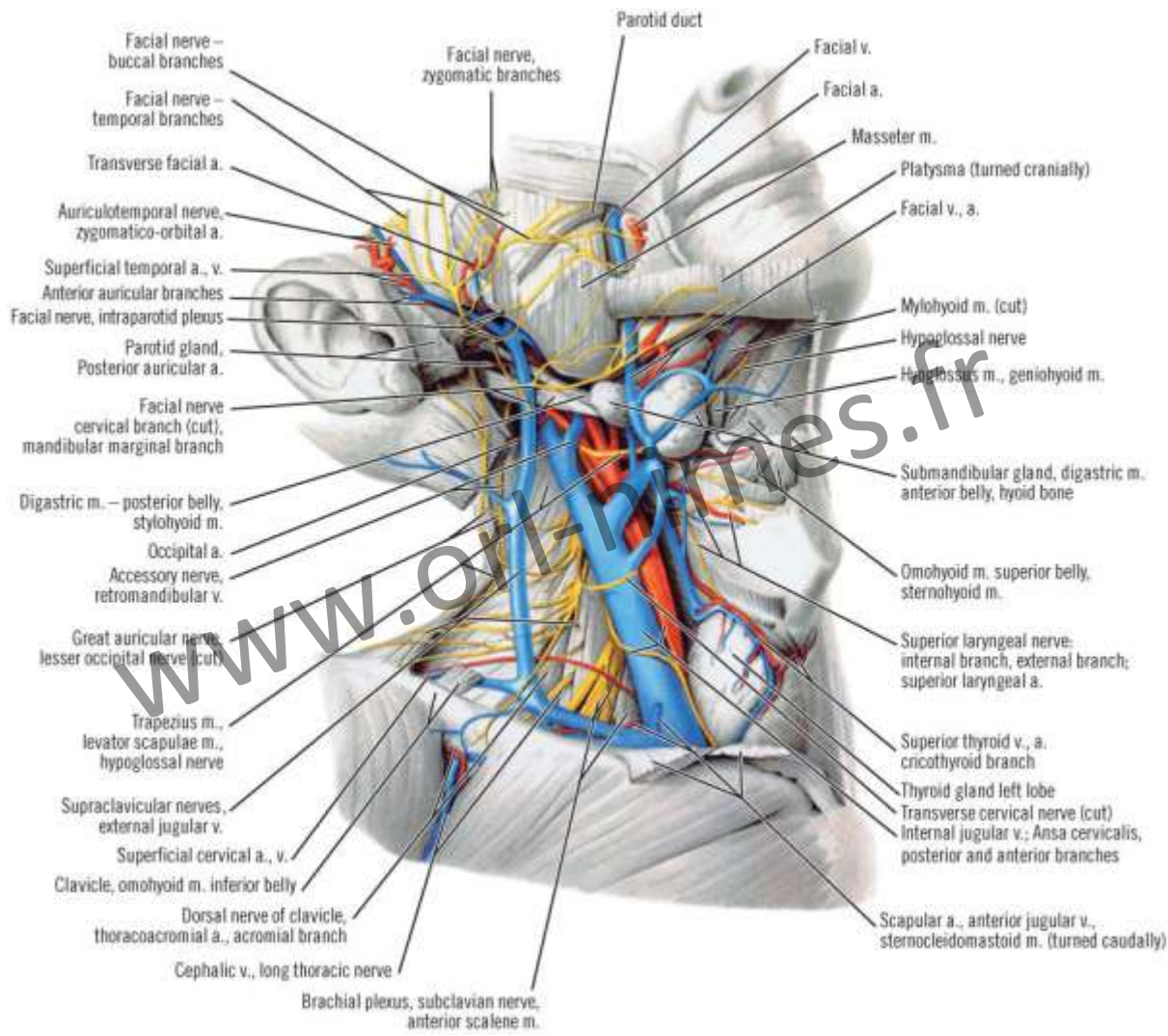


Blood vessels of the neck

(summary)

www.orl-nimes.fr

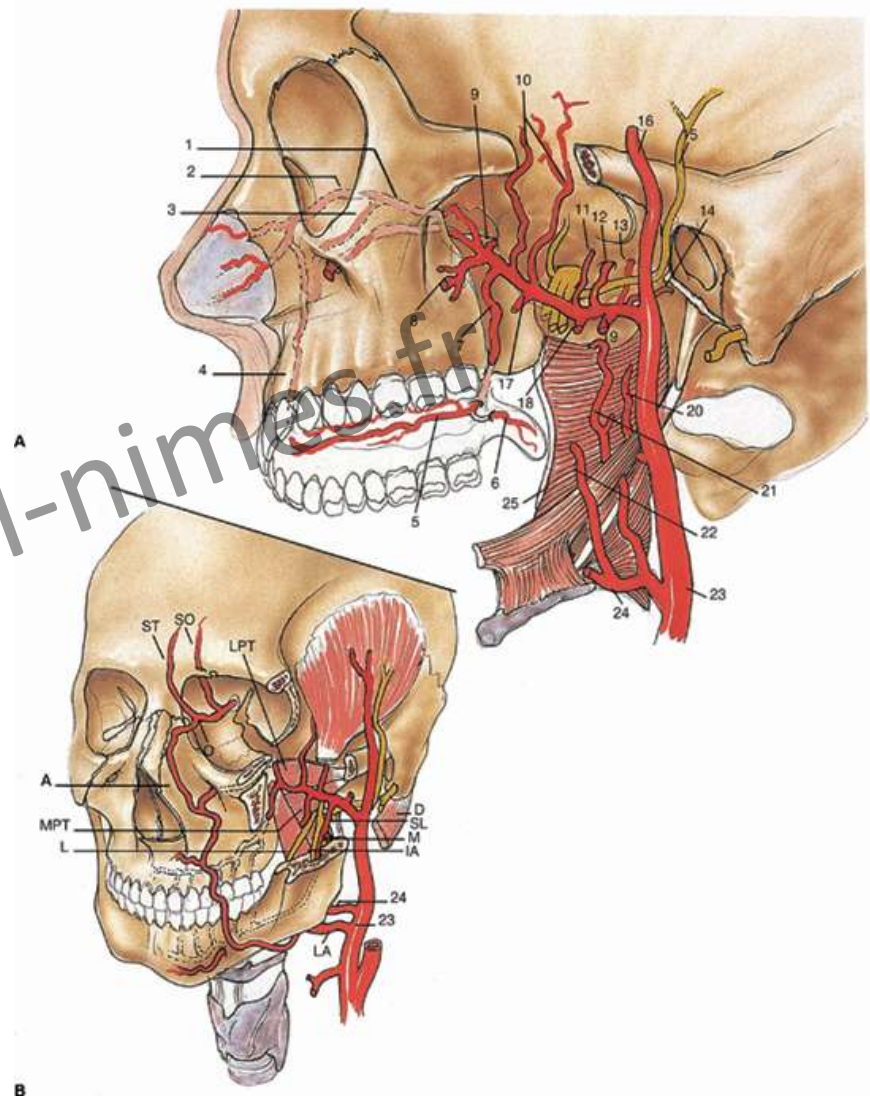
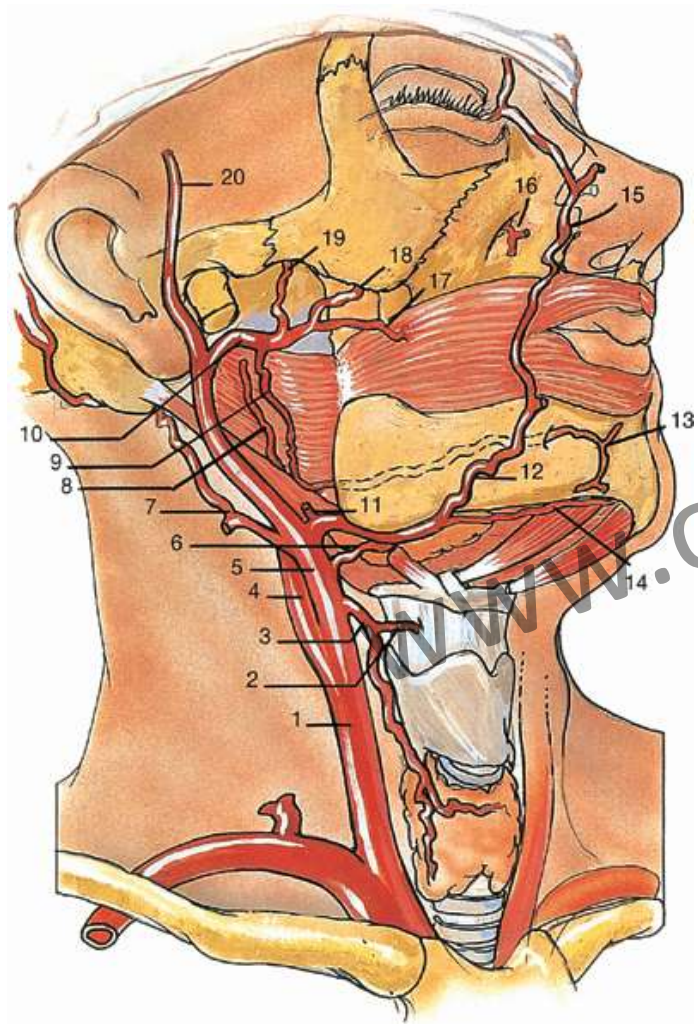


Parotid gland, sternocleidomastoid muscle, supra- and infrahyoid muscles have been partially removed

Arterial supply of the neck

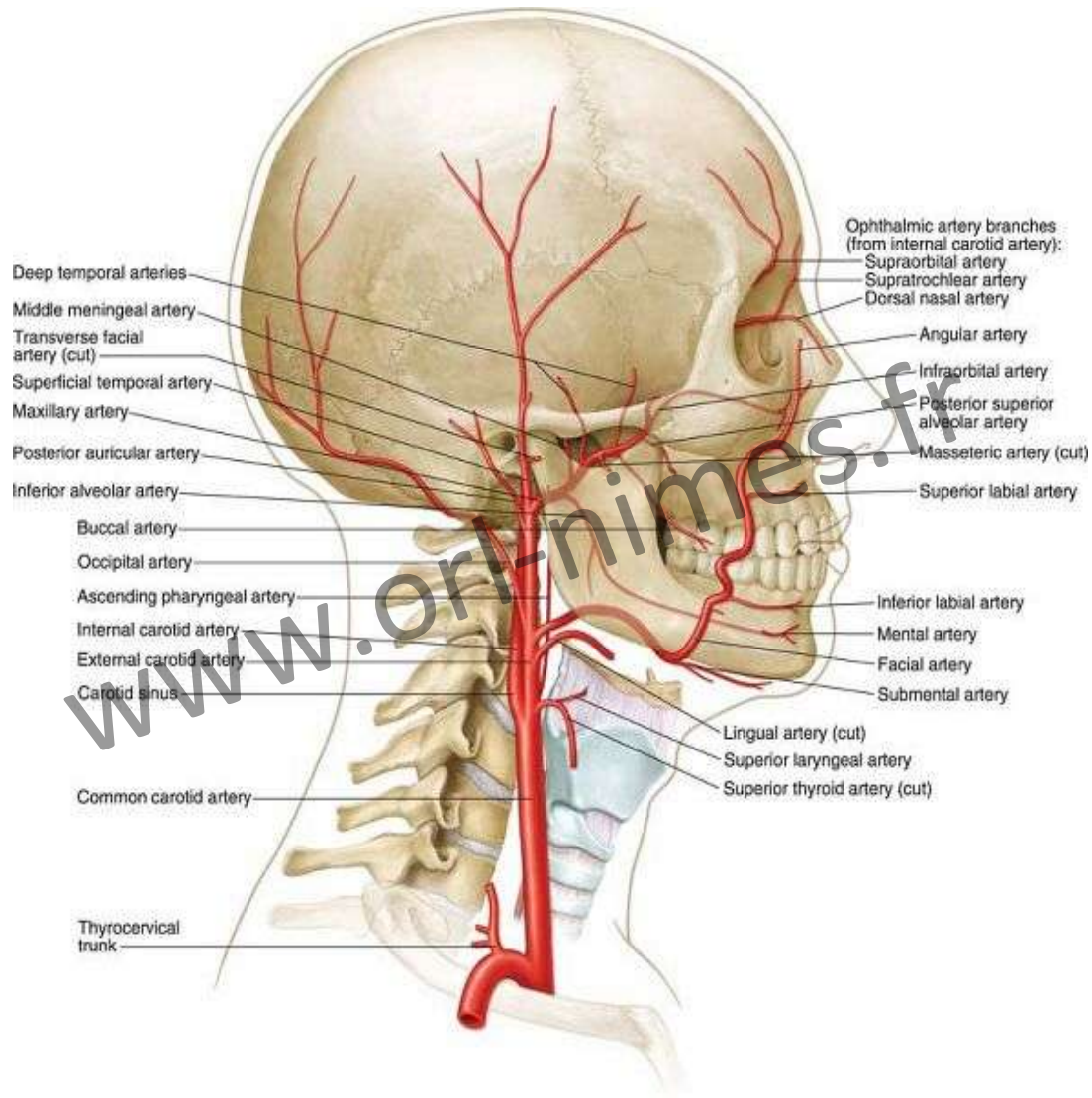
(summary)

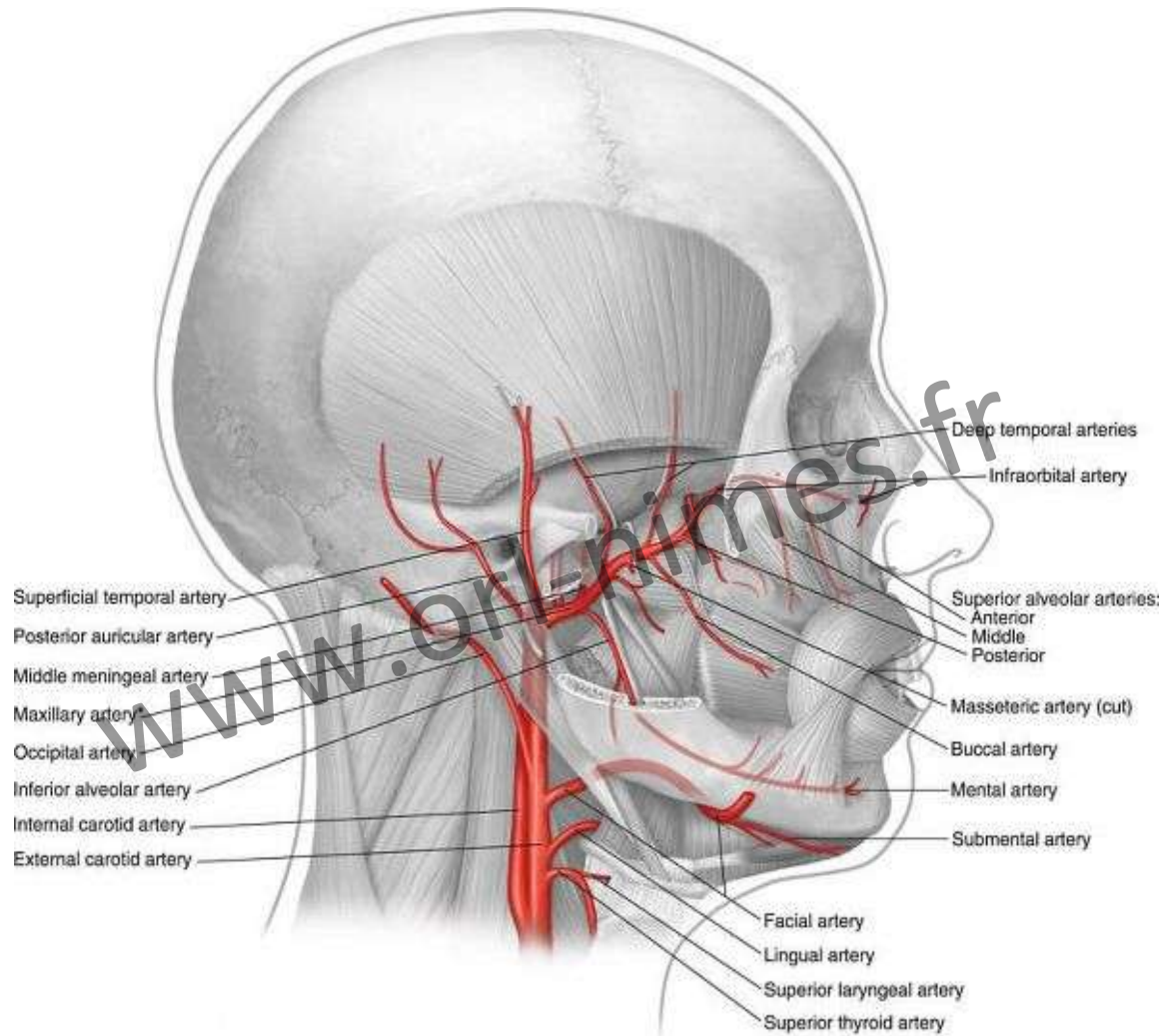
www.orl-nimes.fr



External Carotid Artery

www.orl-nimes.fr

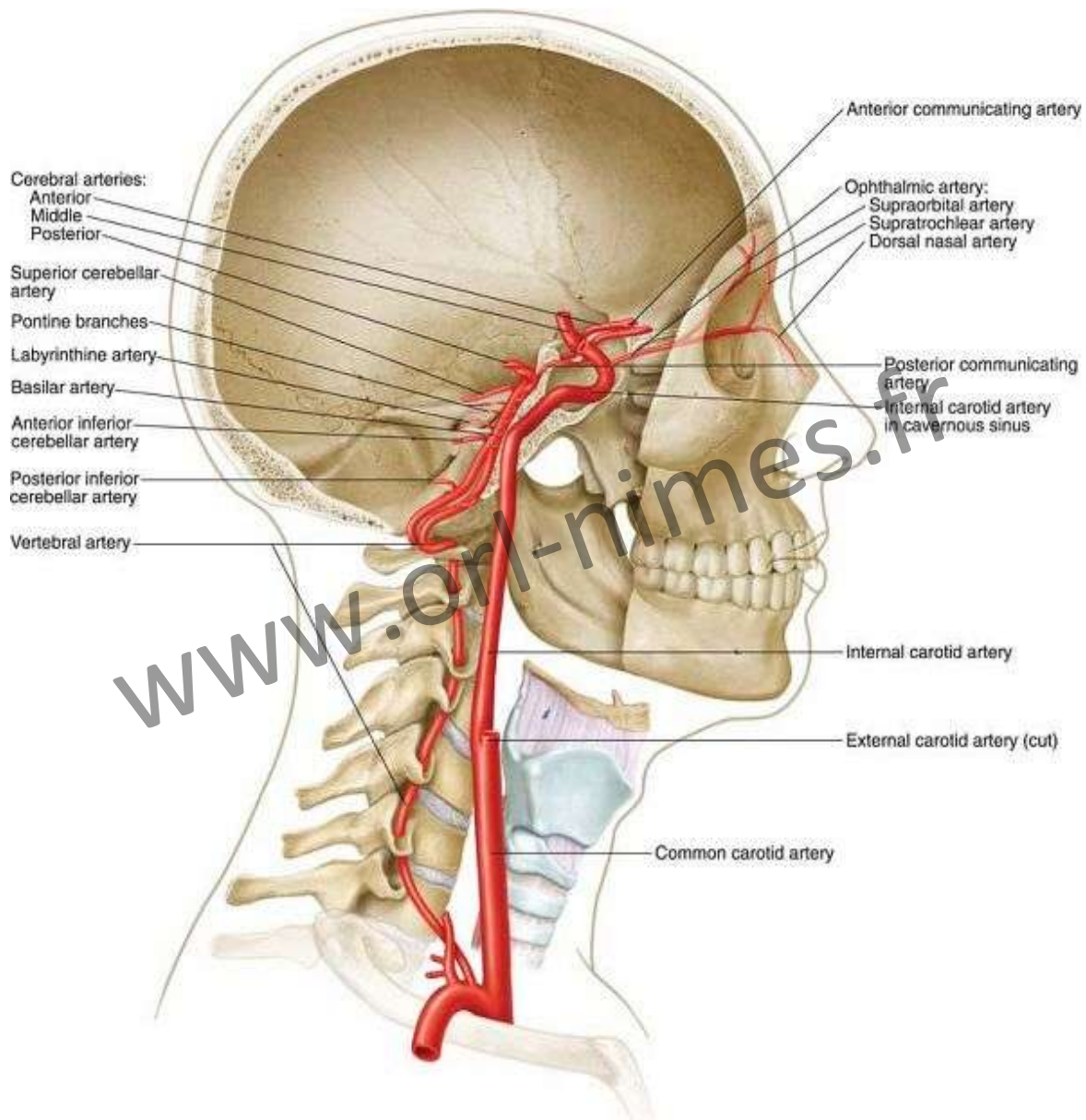




* The maxillary artery may pass medial (42%) or lateral to lateral pterygoid muscle

Internal Carotid and Vertebral Arteries

www.orl-nimes.fr



Veins of the Head and Neck

www.orl-nimes.fr

